


Case Study

## A Case Study Report: Zoledronic Acid Induced Jaw Osteonecrosis in Patient with Bone Metastasis, A Relatively Rare Side Effect

Satish Kumar <sup>1</sup> , A Swapna Moparthi <sup>\*2</sup>, Nagasri Koka <sup>2</sup>, Rupasree Bandla <sup>2</sup>, N.V.Ramarao <sup>2</sup>,  
Ramarao Nadendla <sup>2</sup>

<sup>1</sup> Department of Radiotherapy, Government General Hospital, Guntur, Andhra Pradesh, India

<sup>2</sup> Department of Pharmacy Practice, Government General Hospital, Guntur, Andhra Pradesh, India

Jaw osteonecrosis (JON) is an extraordinary reaction seen in sufferers receiving bisphosphonate remedy for bone retention for the duration of cases of bone metastasis. Nitrogen-based totally bisphosphonates (NBBP) similar to Zoledronic acid whilst injected with intravenous (IV) have a stronger potential to enhance jaw osteonecrosis in comparison with oral treatment. To get the fine healing consequences and to be affected person, it's miles best to apply zoledronic acid every year. This paper reviews the case of an eighty-year-vintage woman affected by endometrial cancer with bone metastasis advanced through Jaw osteonecrosis (JON) after consecutive cycles to offer her Zoledronic acid. Exam reveals early signs and symptoms of Jaw osteonecrosis (JON) in a doctor's record she became tested and discontinued giving zoledronate. Jaw osteonecrosis (JON) happens due to zoledronate perennial infusions. The chance increases for humans with bad oral hygiene due to infections

*Keywords:* Zoledronic acid, Jaw osteonecrosis, Perennial infusion, Negative oral hygiene.

### 1. Introduction

Bisphosphonates are drugs which can be used to save you decay and bone deformities together with fractures. Bisphosphonates inhibit put up-translational protein conversion play a major function in regulating the cellular functions of the osteoclast which includes bone fiber fusion ultimately leading to osteoclast apoptosis [1].

Other studies have proven that continual management of Zoledronic acid reduces bone loss and will increase bone mineral density in women with osteoporosis after menopause, thereby decreasing the threat of fractures particularly related to the hip and spine. This kind of bisphosphonates is commonly properly tolerated and has a nice protection profile [2].

The case defined within the report shows that perennial infusions of zoledronic acid may lead to bisphosphonate-associated JON in the elderly.

---

Correspondence should be addressed to  
Swapna Moparthi; [swapnamoparthi@gmail.com](mailto:swapnamoparthi@gmail.com)

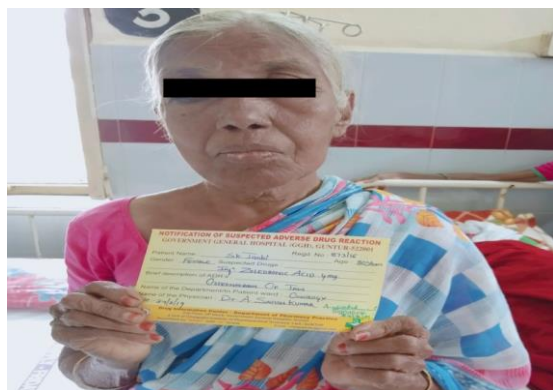© 2022 SHAREme, ISSN (O) 2583 - 3162



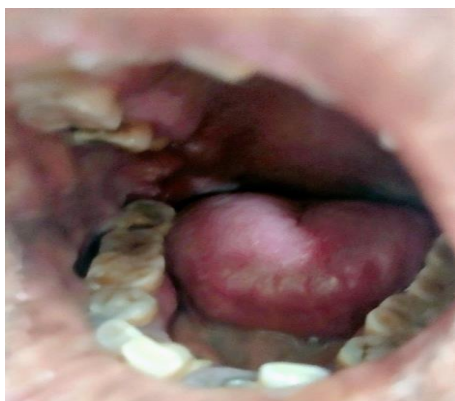This work is licensed under a [Creative Commons Attribution 4.0 International License](https://creativecommons.org/licenses/by-nc-nd/4.0/).

## 2. Case Description

An eighty-year-vintage affected person becomes admitted to the female radiotherapy ward at a government general hospital, Guntur. Current problem situates that she had severe pain in her cheek for approximately a month and had swollen right buccal area that made it not possible for her to open her mouth completely. The wound is seen inside the alveolar region of the third molar Fig. 2.



**Fig.1. Patient issued with an ADR alert card**

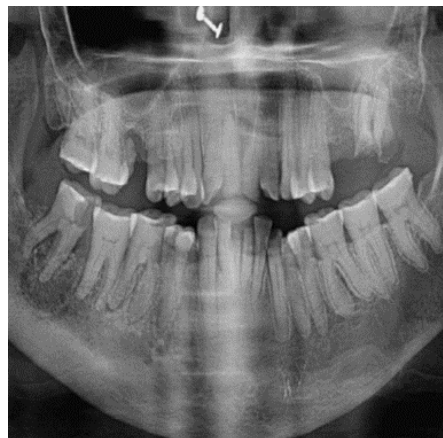

**Fig.2. Ulceration above the right third molar region**

She also complained of purulent discharge from the area of ulceration. Patient had history of Endometrial cancer with bone metastasis and patient is diagnosed as stage IV B of endometrial cancer on 22<sup>nd</sup> January, 2017. Also with a history of radiotherapy. Patient is on monthly Infusion of Zoledronic 4mg since 23<sup>rd</sup> January, 2017.

Currently she visited hospital for the 30th cycle of Zoledronic acid. Physical examination disclosed painful swelling of the cheek and limited mouth opening; there is no record of dental surgical operation and trauma. Patient with records of poor oral hygiene. Physician who did oral examination and recognized

signs like buccal space infection and dental caries and suggested an Orthopantomogram (OPG) for further investigation. Orthopantomogram revealed necrosed lower jaw at right third molar region Fig. 3. Finally she was diagnosed as jaw osteonecrosis. Physician discontinued the Infusion Zoledronic acid 4mg.



**Fig.3. Necrosis at right third molar region**

## 3. Discussion

Bisphosphonates strongly bind to osteoclasts. Osteonecrosis is because of the formation of bisphosphonates in the course of bone regeneration. Consequently, lengthy-time period use of bisphosphonate can be commonplace in the aged. Numerous theories have been proposed to make clear the pathogenesis of JON due to the use of Zoledronic acid. Few touch upon osteoclasts and different angiogenesis for the prevention of angiogenesis [3].

In this case poor dental hygiene and continual use this means that those almost 29 cycles of giving Zoledronic acid for 2 years for five months may additionally cause Jaw Osteonecrosis (JON). Remedy become given a prognosis and the patient turned into launched. In this situation the purpose became observed to be "possible" in keeping with the world health organisation-Uppsala tracking centre (WHO-UMC) assessment scale.

## 4. Conclusion

In recent times Zoledronic acid (Nitrogen primarily based Bisphosphonate) is broadly used to deal with a severe threat of bone metastasis in high-grade most cancers sufferers. Drastically save you bone troubles and specifically fractures [4]. Despite the fact that Zoledronic acid is well tolerated and aspect results are uncommon, long-time period use associated with Jaw

Osteonecrosis, that is extra common in sufferers with bone metastasis, has received Zoledronic acid (Nitrogen based totally Bisphosphonate) intravenously.

Zoledronic acid has been stated to reason Jaw osteonecrosis, which is taken into consideration an unprecedented result. Medicinal drug discontinuation will assist relieve pain in the cheek, although Zoledronic acid is needed to have an effective effect on the majority of patients with metastasis bone cancer.

## REFERENCE

- [1] Matthew t, Bart l, Sundeep k, Bisphosphonates: Mechanism of Action and Role in Clinical Practice; Mayo Clin Proc.83 (9):1032-1045, 2008.
- [2] Lars Rasmusson and Jahan Abtahi; Bisphosphonate Associated Osteonecrosis of the Jaw: An Update on Pathophysiology, Risk Factors, and Treatment; International Journal of Dentistry, Article ID 471035 (2), 2014.
- [3] Ian R, Jacques PB, Burk hard P, etal; intravenous Zoledronic acid in postmenopausal women with low bone mineral density; n engl j med, vol. 346 (9), 2002.
- [4] Ibrahim T, Barbanti F, Giorgio-Marrano G etal.; Osteonecrosis of the Jaw in Patients with Bone Metastases Treated with Bisphosphonates: A Retrospective Study; The Oncologist March vol.13, no.3;330-336, 2008.
- [5] Otto S, Pautke C, Vanden WT, etal; Medication-related osteonecrosis of the jaw: Prevention, diagnosis and management in patients with cancer and bone metastases; Elsevier; vol.69:177-187, September 2018.